

Donor-Related Coccidioidomycosis in Organ Transplant Recipients

Patty W. Wright,^{1,a} Demosthenes Pappagianis,² Mark Wilson,¹ Ana Louro,¹ Stephen A. Moser,¹ Kenneth Komatsu,³ and Peter G. Pappas¹

¹University of Alabama at Birmingham; ²University of California, Davis; and ³Arizona Department of Health Services, Phoenix

Most cases of coccidioidomycosis in organ transplant recipients arise from either primary infection with *Coccidioides immitis* after environmental exposure or from reactivation of latent infection. Herein, we report 2 cases of rapidly fatal, disseminated coccidioidomycosis that occurred in organ transplant recipients who had never lived in or visited an area where *C. immitis* is endemic. Both subjects had received a transplanted organ from the same donor, an individual with unrecognized active coccidioidomycosis at the time of his death.

Coccidioidomycosis is a systemic fungal infection caused by the dimorphic fungus *Coccidioides immitis*, which is endemic in the southwestern United States, northern Mexico, and parts of Central and South America. Primary infection with *C. immitis* is often asymptomatic but may cause a self-limited influenza-like illness or atypical pneumonia [1]. Extrapulmonary disseminated coccidioidomycosis occurs in 5%–10% of symptomatic patients and may involve ≥ 1 organ. Dissemination is more likely to occur among certain ethnic groups, especially among persons of Asian or African descent, and among persons with blood group B [2] and certain class II HLA loci [3]. Diabetes mellitus, pregnancy, advanced HIV disease, and other significant underlying conditions or risk factors, such as chronic glucocorticosteroid therapy and receipt of a solid-organ transplant, are also associated with an increased risk of dissemination [1].

Coccidioidomycosis was first reported among solid-organ

transplant recipients (SOTRs) in the late 1960s [4]. Subsequently, the disease has been increasingly recognized among SOTRs, with the majority (70%) of infections occurring in the first year after transplantation [5]. An incidence as high as 5% has been reported among SOTRs in areas of endemicity, and the rate of mortality associated with disseminated disease has been reported to be up to 72% among these patients [6, 7].

It has been suggested that transmission of *C. immitis* via donor organs is a means of acquisition, but such transmission has been rarely documented. A recent report of probable donor-associated pulmonary coccidioidomycosis in a lung transplant recipient offers strong evidence supporting this potential source of infection [8]. Herein, we report cases of rapidly fatal, disseminated coccidioidomycosis in 2 SOTRs that resulted from transmission of *C. immitis* from a single organ donor with unrecognized coccidioidomycosis.

Case reports. The first SOTR was a 46-year-old white man with cryptogenic cirrhosis who underwent liver transplantation on 9 March 2001. He had never traveled outside of the southeastern United States. On posttransplantation day 13, he developed a clinical presentation of sepsis, which included fever, respiratory failure, altered mental status, hypotension, and leukocytosis. Empirical therapy with broad-spectrum antibacterials and fluconazole was started. An exploratory laparotomy performed on posttransplantation day 15 was unrevealing. Adult respiratory distress syndrome developed, and the patient underwent bronchoscopy with bronchoalveolar lavage (BAL) on posttransplantation day 16. Special stains of BAL specimens did not reveal cytomegalovirus (CMV), acid-fast bacilli, fungi, or other bacteria. Amphotericin B was administered empirically, but the patient died on posttransplantation day 17.

Postmortem examination revealed diffuse microabscesses involving the bone marrow, lungs, kidneys, heart, thyroid, pancreas, brain, liver, and spleen. Histopathological examination revealed innumerable spherules consistent with disseminated *C. immitis* (figures 1 and 2). Premortem BAL fluid and blood cultures grew *C. immitis*. Pretransplantation serum samples were not available for *C. immitis* testing for this patient.

The second SOTR was a 28-year-old black man with end-stage renal disease who received an allograft kidney on the same day (9 March 2001) and from the same donor as SOTR 1. He lived in Mississippi and had never traveled outside of the eastern United States. On posttransplantation day 11, his serum creatinine level was 4.2 mg/dL, and high-dose steroids were administered for 3 days for presumed acute rejection. He became acutely ill with fever, hypoxemia, and dyspnea on posttrans-

Received 4 March 2003; accepted 5 July 2003; electronically published 1 October 2003.

Presented in part: 39th Annual Meeting of the Infectious Diseases Society of America, San Francisco, 25–28 October 2001 (abstract 619).

^a Present affiliation: Vanderbilt University School of Medicine, Nashville, Tennessee.

Reprints or correspondence: Dr. Peter G. Pappas, Div. of Infectious Diseases, University of Alabama at Birmingham, 229 Tinsley Harrison Tower, 1900 University Blvd., Birmingham, AL 35294-0006 (pappas@uab.edu).

Clinical Infectious Diseases 2003;37:1265–9

© 2003 by the Infectious Diseases Society of America. All rights reserved.
1058-4838/2003/3709-0020\$15.00

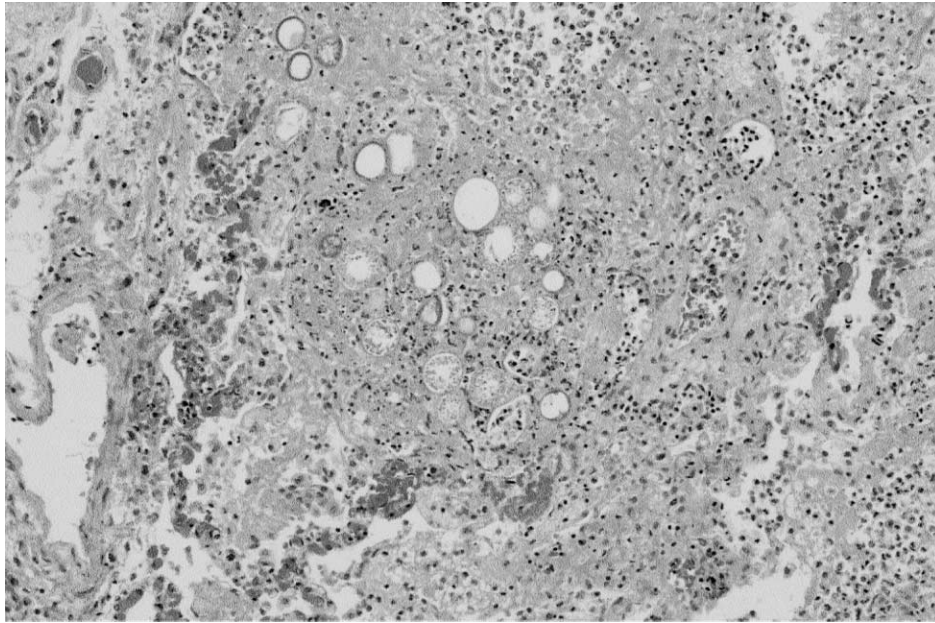


Figure 1. Lung parenchyma demonstrating *Coccidioides* spherules in an autopsy specimen from solid-organ transplant recipient 1, a 46-year-old liver transplant recipient (hematoxylin-eosin stain; low-power magnification).

plantation day 17. Broad-spectrum antibacterial agents were administered, but he developed respiratory failure and adult respiratory distress syndrome requiring ventilatory support. Bronchoscopy was performed, and the results of initial routine studies and special stains of BAL specimens were negative. Fluconazole was added empirically, but the patient died on post-transplantation day 19.

Postmortem examination revealed diffuse microabscesses involving the bone marrow, lungs, kidneys, heart, thyroid, pancreas, brain, testes, liver, and spleen. Histopathological examination demonstrated innumerable spherules consistent with *C. immitis*. Premortem BAL fluid and blood cultures grew *C. immitis*. The results of pretransplantation complement-fixing antibody (CFA) tests for *C. immitis* were negative.

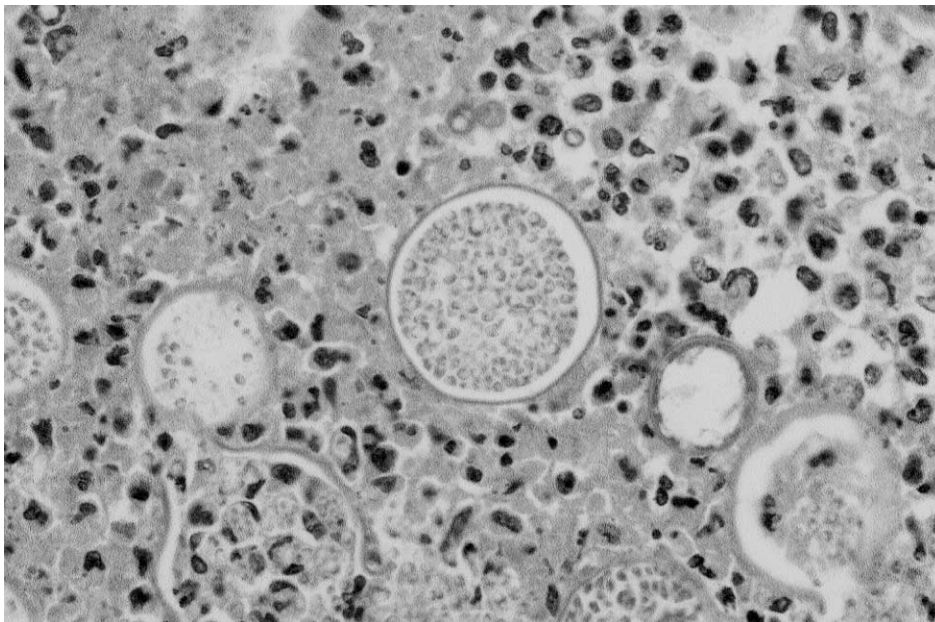


Figure 2. *Coccidioides* spherules in liver parenchyma from an autopsy specimen from solid-organ transplant recipient 1 (periodic acid-Schiff stain; high-power magnification).

A third SOTR, a 58-year-old black woman, received an allograft kidney on 10 March 2001; the donor was the same as for SOTRs 1 and 2. Cold ischemic time for the allograft was almost 37 h. The patient did well postoperatively and was discharged from the hospital on posttransplantation day 16 in good condition.

After the deaths of the 2 other SOTRs, this patient started receiving prophylactic itraconazole (200 mg b.i.d.) and continued this regimen for 3 months. The results of CFA tests performed before and 1 and 10 months after transplantation were negative. She has remained completely asymptomatic for 2 years after transplantation while not receiving any antifungal therapy.

The donor was a 36-year-old black man who presented to a local emergency department on 6 March 2001 complaining of malaise, headache, back pain, and near-syncope. There was a remote history of coccidioidomycosis, but details were unavailable. Shortly after presentation, the patient developed cardiopulmonary arrest with asystole. He was resuscitated, but he never regained neurological function. Support was withdrawn, and his family granted permission for organ donation.

Postmortem examination revealed hypertensive cardiomyopathy and a large pulmonary embolus as the likely cause of death. The liver and kidneys appeared to be normal and were harvested for transplantation. One month later, examination of permanent histopathological specimens of brain and basilar meninges revealed multinucleated giant cells containing fungal organisms consistent with *C. immitis* (figure 3). The remaining tissues did not reveal histological evidence of coccidioidomy-

cosis. Postmortem samples were not obtained for culture. The results of premortem serum CFA tests were positive for *C. immitis*, at a titer of 1:32.

Additional information obtained after the deaths of SOTRs 1 and 2 indicated that the donor had been incarcerated in Arizona from 1995 to 2000. In March 1996, extrapulmonary coccidioidomycosis involving the skin, vertebral body, and sternum was diagnosed; he underwent multiple surgical debridements and was given amphotericin B, followed by fluconazole. He continued receiving fluconazole when he was released from prison in January 2000, at which time the results of CFA tests for *C. immitis* were negative.

Discussion. That donor organs may be a source of transmissible agents, particularly viruses, has been a significant concern throughout the era of solid-organ transplantation [9]. CMV [10, 11], hepatitis B virus [12, 13], and HIV [14–16] may be transmitted from donors to SOTRs. Although it is less common, the transmission of fungi, including *Histoplasma capsulatum* [17], *Aspergillus fumigatus* [18], *Candida albicans* [19], *Scedosporium apiospermum* [20], and *Cryptococcus neoformans* [21, 22], to SOTRs has been well documented. Donor-related transmission of *C. immitis* to SOTRs was convincingly demonstrated only recently in a lung transplant recipient with fulminant pneumonia [7].

This report confirms 2 cases of fatal coccidioidomycosis occurring in SOTRs who had not lived in an area of endemicity and who had received organs from a common donor. The donor had a history of treated disseminated cutaneous and

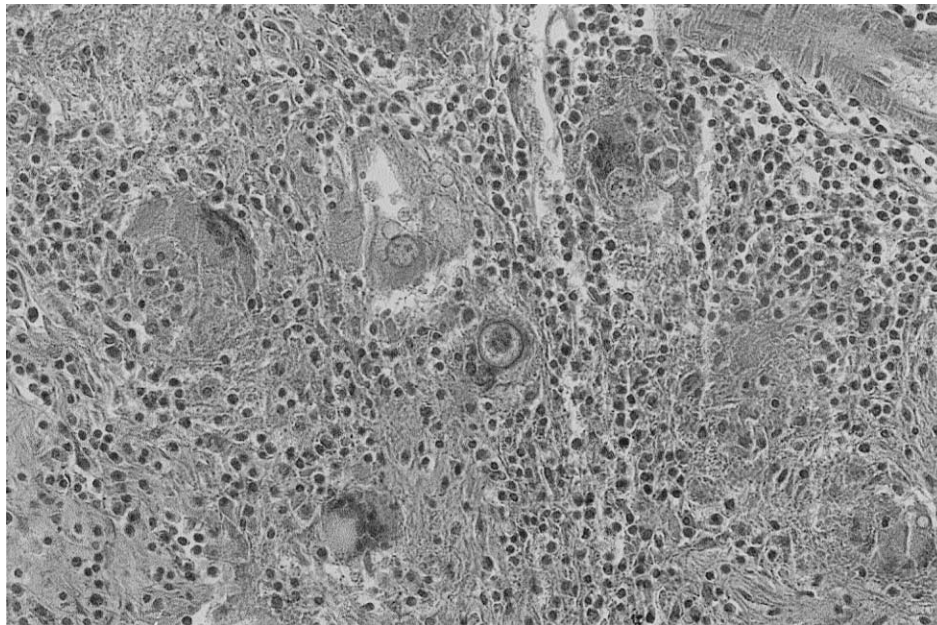


Figure 3. Chronic inflammatory changes associated with *Coccidioides immitis* in autopsy specimens of tissue from the basilar meninges from the organ donor, a 36-year-old man with a history of disseminated coccidioidomycosis years before his death (hematoxylin-eosin stain; low-power magnification).

skeletal coccidioidomycosis, but he had been lost to follow-up and eventually died while having unsuspected CNS coccidioidomycosis. The results of postmortem serological tests for the donor were strongly positive for CFAs to *C. immitis*, at titers that were consistent with disseminated disease. None of the 3 SOTRs had a significant history of travel to an area where *C. immitis* is endemic, and SOTRs 1 and 2 died with overwhelming acute coccidioidomycosis within 3 weeks after undergoing transplantation. These represent, to our knowledge, the first cases of clearly documented donor-related transmission of *C. immitis* to SOTRs living outside a region where coccidioidomycosis is endemic.

Delay in the diagnosis of coccidioidomycosis in the donor had significant implications for 2 of our 3 SOTRs. The 1-month period between the donor's death and the postmortem examination of CNS specimens, the absence of clinical suspicion of active coccidioidomycosis, and the limited access to readily available, rapid, and reliable *C. immitis* serological tests in a region where it is not endemic led to a critical delay in establishing an accurate diagnosis in these patients.

C. immitis is an uncommon pathogen outside of the southwestern United States and northern Mexico; cases occurring outside of the area of endemicity are virtually always imported. Similar difficulty has been encountered in establishing diagnoses of *H. capsulatum* [17] and *Trypanosoma cruzi* [23] infection among transplant recipients residing outside of areas of endemicity for these pathogens. In the recent report by Limaye et al. [17], kidneys from a single donor led to histoplasmosis in 2 recipients 8 and 9 months after transplantation. These cases would likely not have been associated with donor transmission had they not occurred in 2 individuals who did not have a history of residence in or travel to an area where *H. capsulatum* is endemic.

An important but unexplained observation among these transplant recipients is the absence of any clinical or serological evidence of *C. immitis* infection in SOTR 3. Early intervention with systemic antifungal therapy may have abrogated the patient's immunological response to *C. immitis*, or her immunological response may have been delayed because of significant pharmacological immunosuppression. Another possible explanation relates to differences in the handling of the organs after harvest but before reimplantation. SOTRs 1 and 2 received organs within 10 h after harvest, whereas the kidney that SOTR 3 received was kept in cold isotonic solution for 37 h before transplantation. The isotonic solution used to preserve this organ does not contain specific antifungal agents; however, it is conceivable that the viability of *C. immitis* was significantly impaired by prolonged exposure to cold.

In summary, donor-related transmission of *C. immitis* is a rare but serious and potentially preventable complication of

solid-organ transplantation. The greater availability of donor organs from diverse regions increases the likelihood that immunologically naive recipients residing outside of the traditional areas of endemicity will be exposed to geographically restricted organisms, including *C. immitis*. Pretransplantation *C. immitis* serological testing of potential organ donors with a history of complicated coccidioidomycosis could be a useful means to determine evidence of active disease.

Acknowledgment

We wish to thank Ms. Windell Ross for her assistance in preparing this manuscript.

References

1. Stevens DA. Coccidioidomycosis. *N Engl J Med* **1995**;332:1077–82.
2. Deresinski SC, Pappagianis D, Stevens DA. Association of ABO blood group and outcome of coccidioidal infections. *Sabouraudia* **1979**;17:261–4.
3. Louie L, Ng S, Hajjeh R, et al. Influence of host genetics on the severity of coccidioidomycosis. *Emerg Infect Dis* **1999**;5:672–80.
4. Pappagianis D. Epidemiology of coccidioidomycosis. In: Stevens DA, ed. *Coccidioidomycosis: a text*. New York: Plenum Medical Books, **1980**:63–85.
5. Hart PD, Russell E Jr, Remington JS. The compromised host and infection. II. Deep fungal infection. *J Infect Dis* **1969**;120:169–91.
6. Blair JE, Logan JL. Coccidioidomycosis in solid organ transplantation. *Clin Infect Dis* **2001**;33:1536–44.
7. Cohen IM, Galgiani JN, Potter D, et al. Coccidioidomycosis in renal replacement therapy. *Arch Intern Med* **1982**;142:489–94.
8. Tripathy U, Yung GL, Kriett JM, et al. Donor transfer of pulmonary coccidioidomycosis in lung transplantation. *Ann Thorac Surg* **2002**;73:306–8.
9. Gottesdiener KM. Transplanted infections: donor-to-host transmission with the allograft. *Ann Intern Med* **1989**;110:1001–16.
10. Ho M, Suwansirikul S, Dowling JN, et al. The transplanted kidney as a source of cytomegalovirus infection. *N Engl J Med* **1975**;293:1109–12.
11. Betts RF, Freeman RB, Douglas RG, et al. Transmission of cytomegalovirus infection with renal allograft. *Kidney Int* **1975**;8:385–92.
12. Wolf JL, Perkins HA, Schreeder MT, Vincenti F. The transplanted kidney as a source of hepatitis B infection. *Ann Intern Med* **1979**;91:412–3.
13. Lutwick LI, Sywassink JM, Corry RJ, Shorey JW. The transmission of hepatitis B by renal transplantation. *Clin Nephrol* **1983**;9:317–9.
14. Prompt CA, Reis MM, Grillo FM, et al. Transmission of AIDS virus at renal transplantation [letter]. *Lancet* **1985**;2:672.
15. L'age-Stehr J, Schwarz A, Offermann G, et al. HTLV-III infection in kidney transplant recipients [letter]. *Lancet* **1985**;2:1361–2.
16. Schwarz A, Hoffman F, L'age-Stehr J, Tegzess AM, Offermann G. Human immunodeficiency virus transmission by organ donation: outcome in cornea and kidney recipients. *Transplantation* **1987**;44:21–4.
17. Limaye AP, Connolly PA, Sagar M, et al. Transmission of *Histoplasma capsulatum* by organ transplantation. *N Engl J Med* **2000**;343:1163–6.
18. Keating MR, Guerrero MA, Daly RC, Walker RC, Davies SF. Trans-

- mission of invasive aspergillosis from a subclinically infected donor to three different organ transplant recipients. *Chest* **1996**;109:1119–24.
19. Battaglia M, Ditunno P, Fiore T, De Ceglie G, Regina G, Selvaggi FP. True mycotic arteritis by *Candida albicans* in 2 kidney transplant recipients from the same donor. *J Urol* **2000**;163:1236–7.
 20. an der Vliet JA, Tidow G, Kootstra G, et al. Transplantation of contaminated organs. *Br J Surg* **1980**;67:596–8.
 21. Kanj SS, Welty-Wolf K, Madden J, et al. Fungal infections in lung and heart transplant recipients: report of 9 cases and review of the literature. *Medicine (Baltimore)* **1996**;75:142–56.
 22. Ooi BS, Chen BT, Lim CH, Khoo OT, Chan KT. Survival of a patient transplanted with a kidney infected with *Cryptococcus neoformans*. *Transplantation* **1971**;11:428–9.
 23. Zayas CF, Perlino C, Caliendo A, et al. Chagas disease after organ transplantation—United States, 2001. *MMWR Morb Mortal Wkly Rep* **2002**;51:210–2.